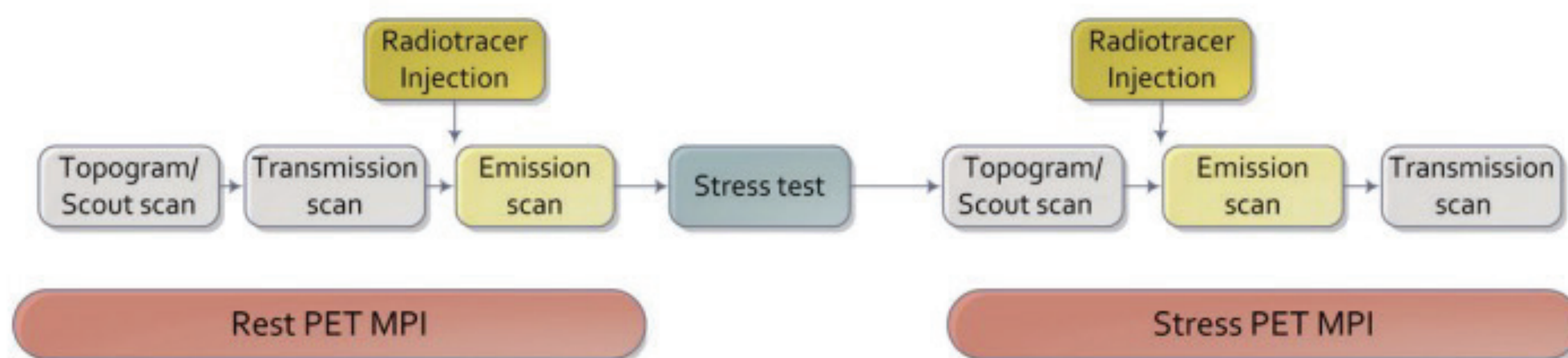


PET Myocardial Perfusion Imaging (MPI)

Typical Workflow



Typical Dosimetry and Duration of Imaging (numbers refer to either rest or stress imaging)

Dosing (based on 3D imaging):

82-Rubidium: 10-20 mCi

N-13 Ammonia: 10-20 mCi

Duration of scan:

82-Rubidium: 3-10 min

N-13 Ammonia: 10-15 min

*Decay period of 20-50 minutes required between N-13 doses

Exercise for PET MPI

- One IV required.
- Only N-13 ammonia can be used for exercise (longer half-life than 82-Rubidium) but cannot obtain myocardial blood flow measurements as patient will not be in scanner at the time of radiotracer injection (maximum exercise capacity, preferably >85% maximum age predicted heart rate).
- Radiotracer dose must account for decay during the delay to transport patient to the scanner.
- Imaging is started as soon as possible but may be impacted by patient breathing.

Pharmacologic Stress Agents for PET MPI

For all vasodilators and dobutamine, imaging should be started concurrently with radiotracer administration to capture the bolus for myocardial blood flow quantification.

Regadenoson

- Regadenoson is injected from a pre-filled syringe over 10 seconds followed by a 10 mL saline flush.
- Radiotracer is injected at least 20 seconds after flush (some data supports waiting longer to achieve peak hyperemia).

Adenosine

- Two IVs required.
- Administer adenosine over 4-6 minutes with injection of radiotracer 2 minutes after starting the infusion. Continue adenosine infusion for 2 minutes or until 6 minutes in total have been reached.

Dipyridamole

- One IV required.
- Give dipyridamole as a continuous infusion over 4 minutes with radiotracer given about 3 minutes after infusion completion.

Dobutamine

- Two IVs required.
- Under the guidance of a certified clinician, dobutamine is increased until 85% maximum age predicted heart rate is achieved. Atropine can be used with appropriate guidance if target heart rate is not achieved and there are no contraindications (e.g., glaucoma, urinary retention).
- Infusion should continue throughout radiotracer administration.
- Imaging is started upon completion of radiotracer infusion.